

CASE REPORT

Huge left atrial thrombus infected with aspergillusfumigatus

Emrullah Kiziltunc ¹, Gulden Aydogdu Tacoy ², Zeynep Sahika Aki ³, Selcuk Ozkan ⁴

1. Numune Education and Research Hospital, Cardiology Department, Ankara, Turkey. 2. Gazi University School of Medicine, Cardiology Department, Ankara, Turkey. 3. Gazi University School of Medicine, Haematology Department, Ankara, Turkey. 4. Kecioren Education and Research Hospital, Cardiology Department, Ankara, Turkey.

Correspondence: Emrullah Kiziltunc. Address: Ankara Numune Education and Research Hospital, Cardiology Department, 06230, Sıhhiye, Ankara, Turkey. Email: e.kiziltunc@gmail.com

Received: February 7, 2014
DOI: 10.5430/ijdi.v1n2p97

Accepted: May 13, 2014

Online Published: June 4, 2014

URL: <http://dx.doi.org/10.5430/ijdi.v1n2p97>

Abstract

Twenty three year old man with Hodgkin lymphoma had a resistant fever although treatment with broad spectrum antibiotics. Transthoracic echocardiography was performed to explain the origin of the fever and a huge mass was detected in the left atrium. Cardiac magnetic resonance imaging was performed and reported as intracardiac thrombus. Patient was referred to surgery. Culture of the surgical material favored to *Aspergillus fumigatus*. Voriconazole treatment was started and patient recovered. The authors report overlapping two different clinical situations, intracardiac thrombus and fungal infective endocarditis.

Keywords

Aspergillus fumigatus, Endocarditis, Intracardiac thrombus, Transthoracic echocardiography, Cardiac magnetic resonance imaging

1 Introduction

Intracardiac masses may be due to primary or secondary cardiac tumors, vegetations and thrombus. There is an increased risk for cardiac invasion/involvement, endocarditis and thrombus formation in malignancy patients. Cardiac magnetic resonance imaging (CMRI) generally is preferred for assessment of a cardiac mass and offering clues as to the type of tumor that is present malign or benign. Here we present a case of Hodgkin's disease with a huge left atrial thrombus infected with *aspergillus fumigatus*.

2 Case report

Twenty three year old male patient was diagnosed with stage IVB (pleural and pericardial involvement) nodular sclerosis syncytial variant Hodgkin's disease 4 years ago. He was refractory to remission induction chemotherapy with ABVD (adriamycin, bleomycine, vincristine, and dacarbazine). Thirty six Gy radiotherapy was given to mediastinal bulky disease. Three cycles of ICE chemotherapy was given (iphosphamide, carboplatin, and etoposide) for salvage treatment. Partial remission was obtained after 3 cycles of ICE chemotherapy and radiotherapy. Autologous hematopoietic stem cell transplantation (AHSCT) was performed after high dose chemotherapy with BEAM conditioning regimen because of refractory disease. PET/CT examination demonstrated complete remission 2 months after AHSCT. Echocardiographic

examination and the cardiac rhythm were in normal limits before AHSCT. Four months later, he developed refractory relapse to salvage chemotherapy regimen and underwent HLA mismatched unrelated donor allogeneic HSCT. He received cyclosporine A and mycophenolate mofetil for graft versus host disease (GVHD) prophylaxis. Cytomegalovirus polymerase chain reaction (CMV PCR) and galactomannan antigenemia tests were performed weekly for possible infections. On day +7 after allogeneic HSCT acute grade 2 skin GVHD has evolved and 1 mg/kg/day methylprednisolone was given for treatment. During early posttransplantation period caspofungin antifungal treatment was given for possible fungal pneumonia. Three months after HSCT transthoracic echocardiographic examination revealed normal findings except slight thickness of mitral valve. There was no arrhythmia on electrocardiography (ECG). On day +173 of transplantation, recurrent fever has evolved while receiving broad spectrum antibiotics for 17 days. All of the blood cultures were negative. Transthoracic echocardiographic (TTE) examination was performed for origin of fever and to evaluate central venous catheter tip. A huge left atrial mass which was prolapsing into the left ventricle with atrial systole just located below the anterior leaflet of the mitral valve (see Figure 1) was detected. An urgent cardiac MRI was performed to evaluate nature of the mass and reported as a thrombus arising from the left atrial appendix with a thin pedunculus, extending just below the mitral valve (see Figure 2). The patient was referred to surgery immediately. Macroscopic and histopathological examination of the surgical specimen was consistent with thrombus. No bacteria or fungal materials were seen on microscopic examination. *Aspergillus fumigatus* was detected in culture of the specimen. Intravenous voriconazole treatment was continued for the *Aspergillus fumigatus* endocarditis and the patient recovered and discharged to home.

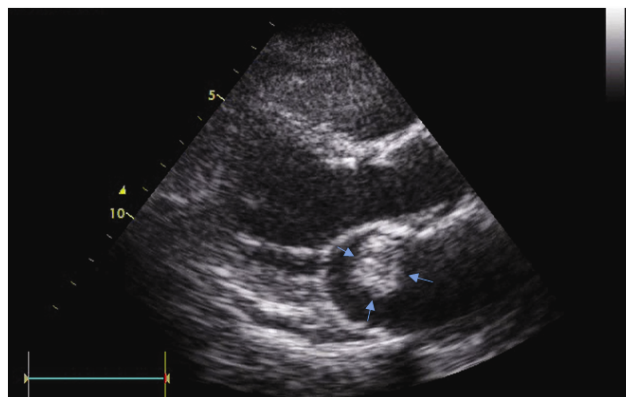


Figure 1. Parasternal long axis view is showing mass in left atrium.

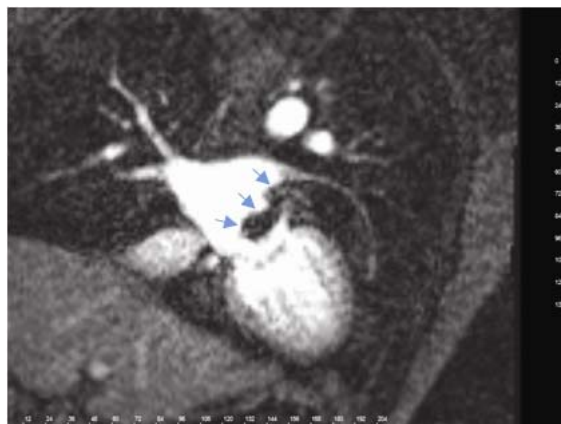


Figure 2. Cardiac MR is showing the mass arising from left atrial appendix.

3 Discussion

Hematologic malignancies may lead multiple cardiac problems either cardiac involvement of the primary disease or a complication due to the treatment. Pericardial effusion^[1] and intracardiac masses^[2] can be seen as a cardiac involvement of the primary disease. Immunosuppressive and wide spectrum antibiotics treatments^[3] can result in bacterial or fungal endocarditis. Coronary artery lesions, constrictive pericarditis, valvular thickening and regurgitation are the unwanted side effects of radiotherapy^[4, 5]; and also dilate cardiomyopathy can be developed due to toxicity of the chemotherapeutics^[6]. In our case, there was a huge left atrial thrombus due to primary disease and an overlapping aspergillus endocarditis due to immunosuppressive therapy.

Intracardiac masses have been reported in all chambers of the heart^[6]. Exploring the nature of the mass, which is the indicator of the prognosis, is critical. Direct tumor invasion or clot formation can be detected as a mass with TTE and it's hard to differentiate a thrombus from a neoplastic mass with echocardiographic imaging. Cardiac MRI generally is preferred imaging modality for these purpose. Primary cardiac neoplasias are rare and myxoma is the most common primary cardiac neoplasm^[7]. In contrast to primary malignant cardiac tumors, metastatic involvement of the heart is relatively common and a sign of poor prognosis^[8]. Although left atrial thrombus can be usually seen with atrial arytmiias especially with atrial fibrillation, patients with hematologic malignancies have a different physiopathology to generate thrombus. In this group of patients, there is a tendency for clot formation due to different causes such as malign cell derived procoagulant factors, inflammatory cytokines affecting coagulation cascade, prothrombotic effect of the treatment agents. This prothrombotic state can cause especially deep venous thrombus^[9], with or without pulmonary embolism, thrombosis in other vascular sites and rarely intracardiac thrombus can be seen. In our patient there was a huge left atrial thrombus.

Fungal endocarditis is less common than bacterial endocarditis. There are different series which shows fungal etiology ranging from 1.6% to 6%^[10, 11] of all endocarditis. Patients with hematologic malignancy have an increased risk for fungal endocarditis because of the nature of the disease, the immunosuppressive effects of the chemotherapeutic drugs, indwelling central venous catheters and wide spectrum antibiotic use. *Candida* species are the most common agents but aspergillus species prevalence is increasing^[12]. It's hard to diagnose aspergillus endocarditis. Atypical clinical presentation and blood cultures which are rarely positive makes it difficult to recognize^[13]. In our case the one clinical presentation was fever. There was neither embolic phenomenon nor immunologic phenomenon. The blood cultures were negative and there was no structural heart disease. Patients with immunosuppression (hematologic malignancies, solid organ transplants etc.) who have unknown source of fever must be a debatable endocarditis although blood cultures are negative. Suspicion of endocarditis in these patients is crucial because the diagnosis depends only on the suspicion. Serial echocardiographic examinations are critical for the diagnosis of culture negative and fungal endocarditis. Because of the atypical clinical presentation and failure of isolating the microorganism, demonstration of vegetation is the most powerful way of the diagnosis. As in our patient, many of the patients have atypical symptoms at the beginning and the echocardiographic examinations were normal. With serial examinations the new vegetations can be shown and this can be the only way of diagnosis^[14, 15]. In general, aspergillus endocarditis effects the valves^[16] or intracardiac device leads^[11]. Sometimes mural aspergillus endocarditis can be seen^[15-17]. In our case there was an individual thrombus separate from valves which was infected with *aspergillus fumigatus*. Aspergillus endocarditis is a highly mortal disease^[18] and the treatment requires multidisciplinary approach. Cardiologist, cardiovascular surgeon and infection disease expert must determine the treatment modalities, time for surgery, and antibiotic treatment duration. As a classical knowledge for fungal endocarditis, surgery requires nearly all of the aspergillus endocarditis cases. Radical debridement of the necrotic tissue and vegetation and if necessitate valve replacement or extracting devices may be needed. The agents for medical treatment include amphotericine B, itraconazole, flucytosine, rifampin. Currently voriconazole is the most popular agent with fewer side effects and better survival rates than amphotericine B^[19], and it is approved for the initial treatment of invasive aspergillosis.

4 Conclusion

Intracardiac thrombus formation and infective endocarditis can be seen in patients with haematologic malignancy. Overlapping of these two conditions is more problematic. At the treatment phase, cardiologist, cardiovascular surgeon and infection disease expert should make the decision together. In a case of aspergillus endocarditis with a huge intracardiac thrombus, surgical debridement and systemic antifungal administration should be the treatment modality.

References

- [1] Armstrong WF, Ryan T eds. Feigenbaum's Echocardiography, Seventh Edition. Philadelphia, PA: Lippincott Williams & Wilkins. 2010; 241-262.
- [2] Armstrong WF, Ryan T eds. Feigenbaum's Echocardiography, Seventh Edition. Philadelphia, PA: Lippincott Williams & Wilkins. 2010; 711-739.
- [3] Khayr W, Haddad RY, Noor SA. Infections in hematological malignancies. *Dis Mon.* 2012. Apr; 58(4): 239-249. <http://dx.doi.org/10.1016/j.disamonth.2012.01.001>
- [4] Glanzmann C1, Kaufmann P, Jenni R, Hess OM, Huguenin P. Cardiac lesions after mediastinal irradiation for Hodgkin's disease. *Radiother Oncol.* 1994 Jan; 30(1): 43-54. [http://dx.doi.org/10.1016/0167-8140\(94\)90008-6](http://dx.doi.org/10.1016/0167-8140(94)90008-6)
- [5] Hull MC, Morris CG, Pepine CJ, Mendenhall NP. Valvular dysfunction and carotid, subclavian, and coronary artery disease in survivors of hodgkin lymphoma treated with radiation therapy. *JAMA.* 2003 Dec 3; 290(21): 2831-2837. <http://dx.doi.org/10.1001/jama.290.21.2831>
- [6] Keulenaer G, Force T. Special Problems in Myocarditis and cardiomyopathy: Toxic Cardiomyopathy, Cancer Drugs and Herceptin. In: Crawford MH, Dimarco JP, Paulus WJ eds. *Cardiology.* Philadelphia, PA: Mosby Elsevier. 2010; 1110-1113.
- [7] Pucci A, Gagliardotto P, Zanini C, Pansini S, di Summa M, Mollo F. Histopathologic and clinical characterization of cardiac myxoma: review of 53 cases from a single institution. *Am Heart J.* 2000; 140(1): 134. <http://dx.doi.org/10.1067/mhj.2000.107176>
- [8] Silvestri F, Bussani R, Pavletic N, Mannone T. Metastases of the heart and pericardium. *G Ital Cardiol.* 1997; 27(12): 1252.
- [9] Castelli R, Ferrari B, Cortelezzi A, Guariglia A. Thromboembolic complications in malignant haematological disorders. *CurrVascPharmacol.* 2010 Jul; 8(4): 482-494. <http://dx.doi.org/10.2174/157016110791330799>
- [10] Bayer AS, Scheld M. Endocarditis and intravascular infections. In: Mandell GL, Bennett JE, Dolin R, eds. *Mandell, Douglas and Bennett's principles and practice of infectious diseases.* Philadelphia, PA: Churchill Livingstone. 2000; 857-902.
- [11] Karchmer AW. Infections on prosthetic valves and intravascular devices. In: Mandell GL, Bennett JE, Dolin R, eds. *Mandell, Douglas and Bennett's principles and practice of infectious diseases.* Philadelphia, PA: Churchill Livingstone. 2000; 903-917.
- [12] Ellis ME, Al-Abdely H, Sandridge A, Greer W, Ventura W. Fungal endocarditis: evidence in the world literature, 1965-1995. *Clin Infect Dis.* 2001; 32: 50-62. <http://dx.doi.org/10.1086/317550>
- [13] Woods GL, Wood P, Shaw BW. Aspergillus endocarditis in patients without prior cardiovascular surgery: report of a case in a liver transplant recipient and review. *Rev Infect Dis.* 1989; 2: 263-271. <http://dx.doi.org/10.1093/clinids/11.2.263>
- [14] Leong R, Gannon BR, Childs TJ, Isotalo PA, Abdollah H. Aspergillus fumigatus pacemaker lead endocarditis: a case report and review of the literature. *Can J Cardiol.* 2006; 22(4): 337-340. [http://dx.doi.org/10.1016/S0828-282X\(06\)70919-9](http://dx.doi.org/10.1016/S0828-282X(06)70919-9)
- [15] Mullen P, Jude C, Borkon M, Porterfield J, Walsh TJ. Aspergillus mural endocarditis: Clinical and echocardiographic diagnosis. *Chest.* 1986; 90: 451-452. <http://dx.doi.org/10.1378/chest.90.3.451>
- [16] Xie L, Gebre W, Szabo K, Lin JH. Cardiac Aspergillosis in Patients With Acquired Immunodeficiency Syndrome. *Arch Pathol Lab Med.* 2005; 129: 511-515.
- [17] Peterson SP, Schiller N, Stricker RB. Failure of two-dimensional echocardiography to detect aspergillus endocarditis. *Chest.* 1984; 85: 291-294. <http://dx.doi.org/10.1378/chest.85.2.291>
- [18] Pierotti LC, Baddour LM. Fungal endocarditis. *Chest.* 2002; 122: 302-310. <http://dx.doi.org/10.1378/chest.122.1.302>
- [19] Herbrecht R, Denning DW, Patterson TF, Bennett JE, Greene RE, Oestmann JW, et al. Voriconazole versus amphotericin B for primary therapy of invasive aspergillosis. *NEngl J Med* 2002; 347: 408-15. <http://dx.doi.org/10.1056/NEJMoa020191>